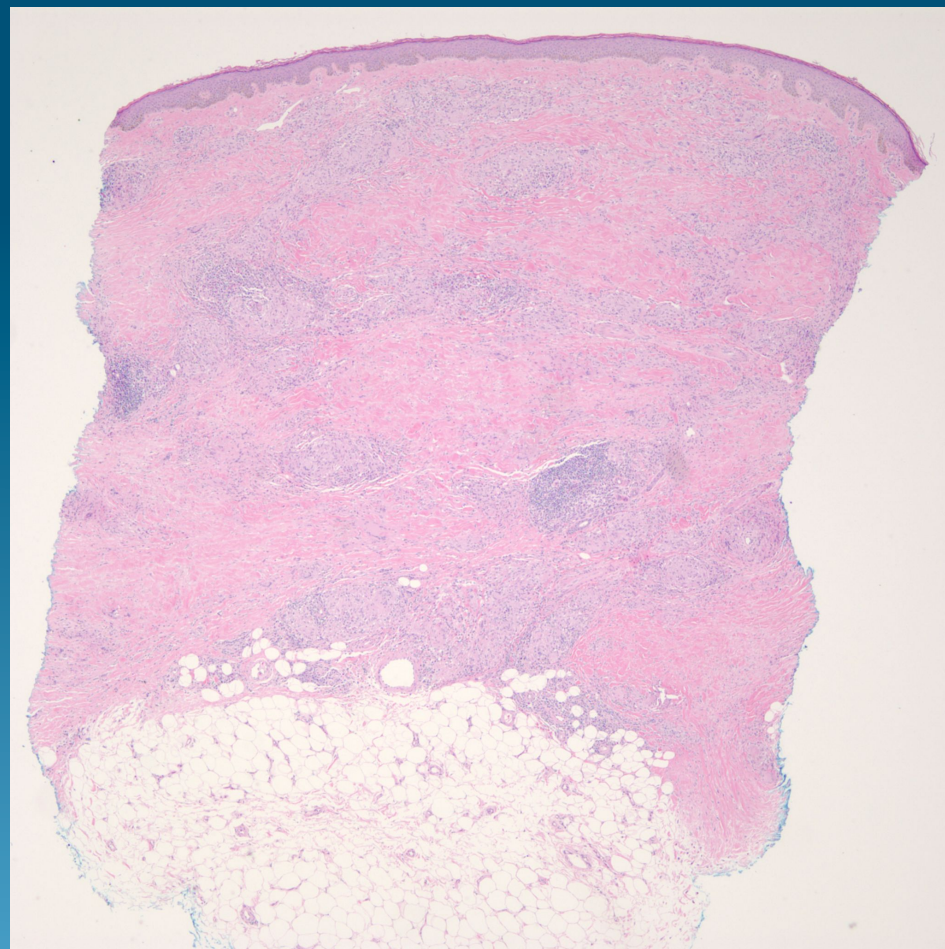
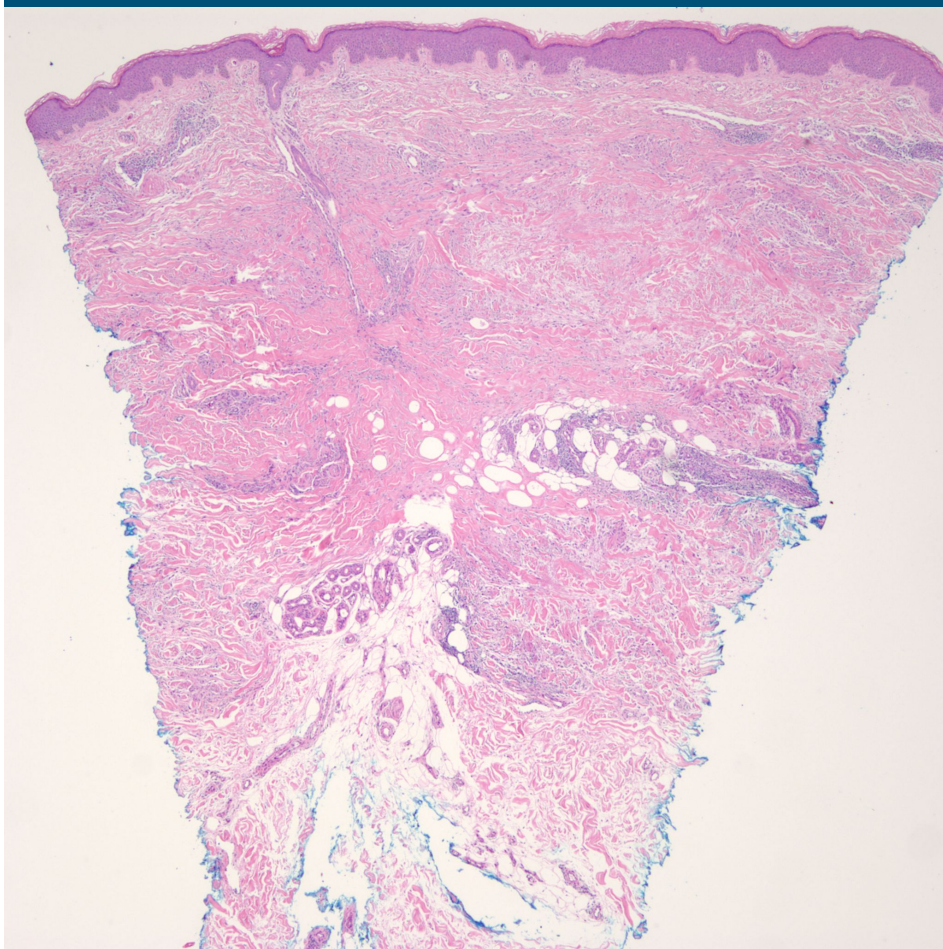
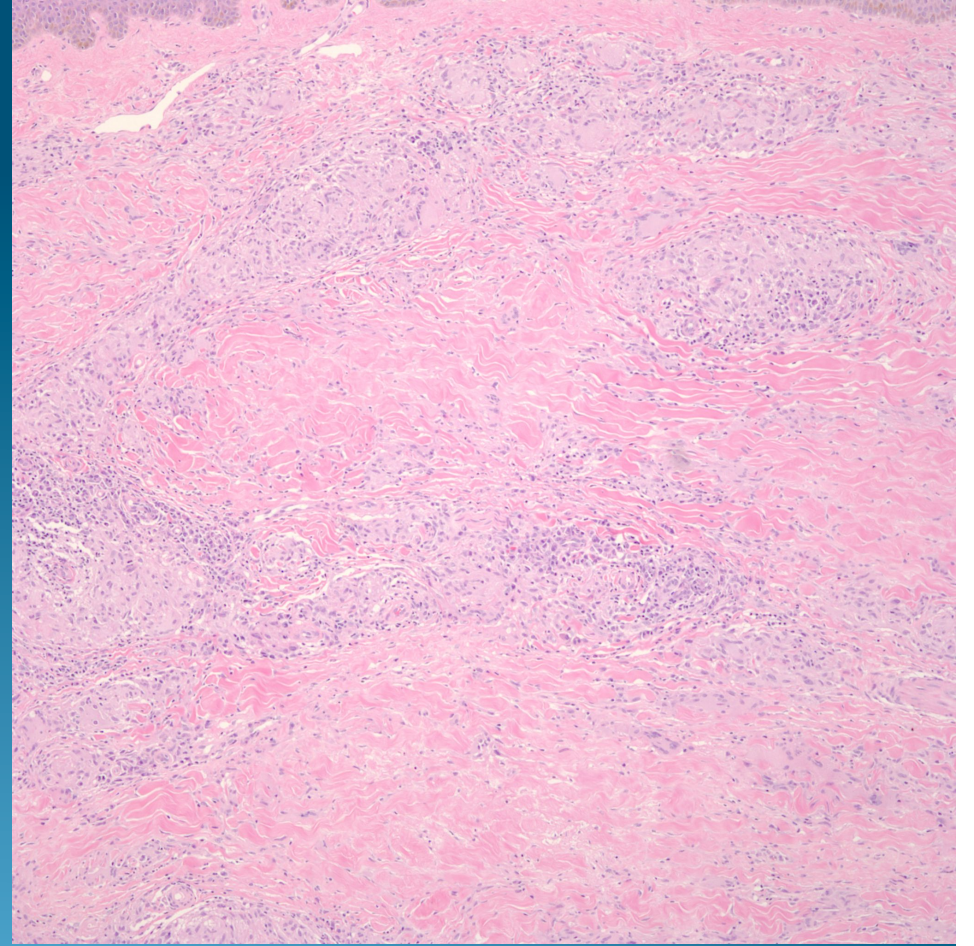
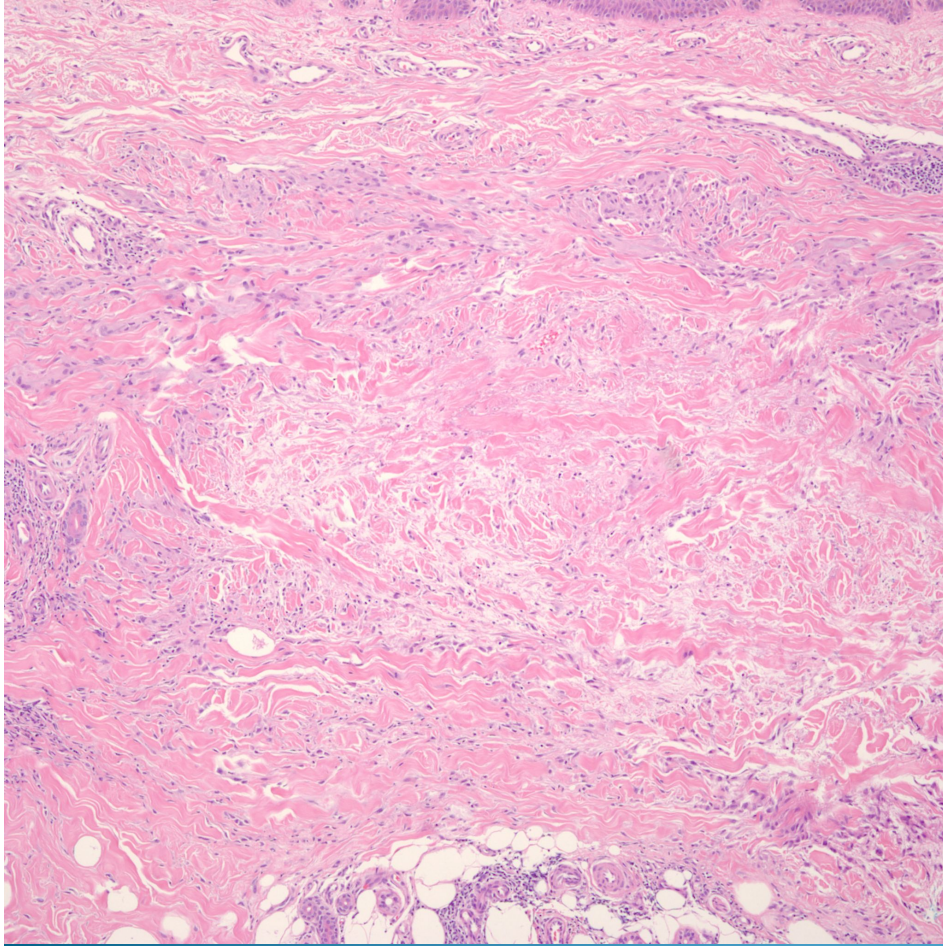
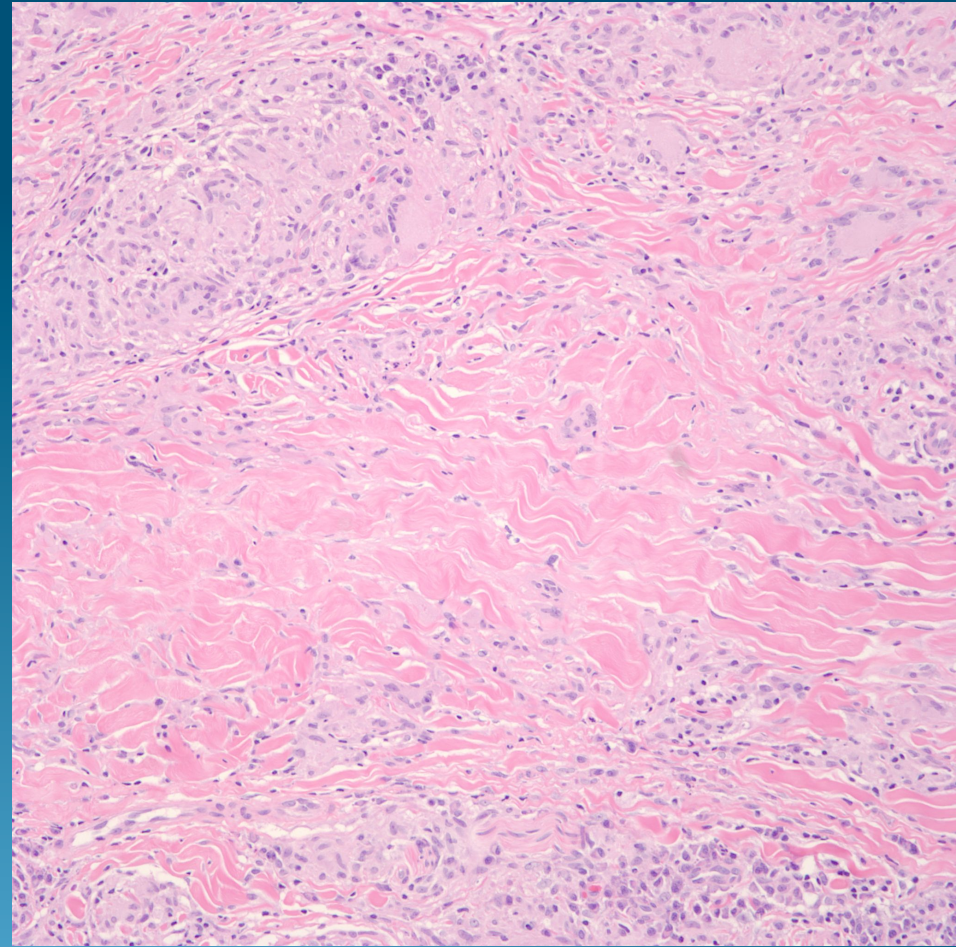
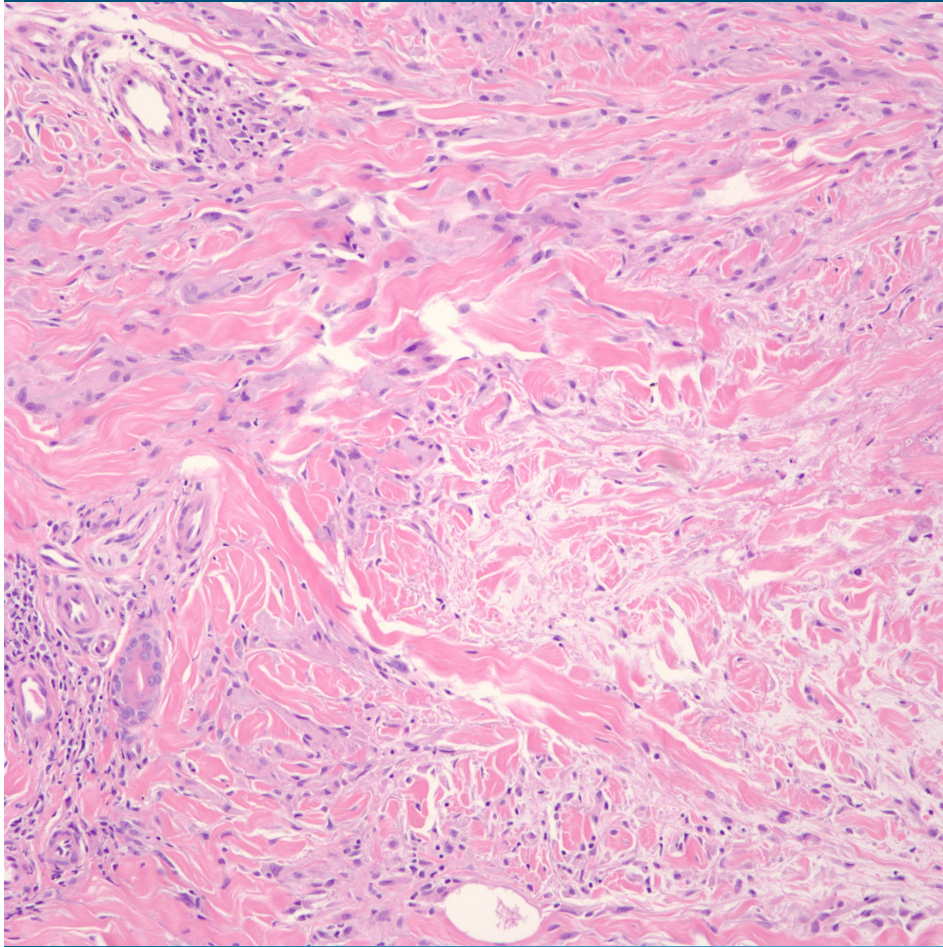
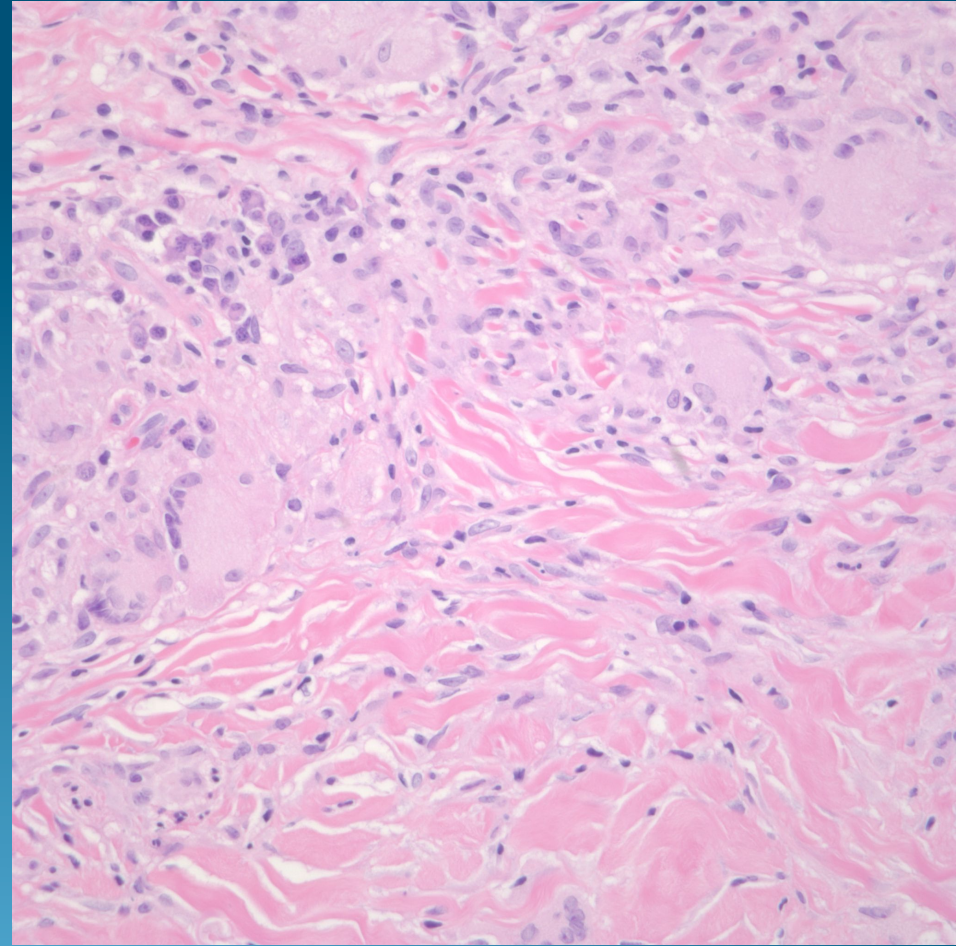
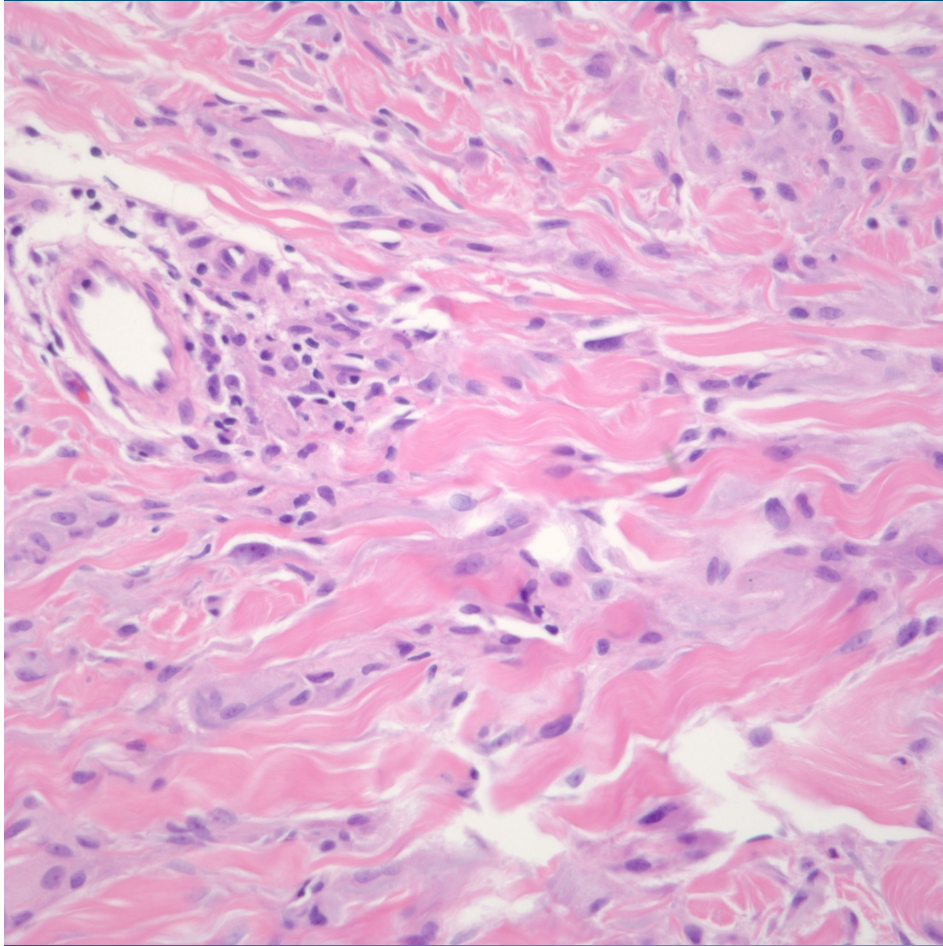


Granuloma Annulare or Necrobiosis Lipoidica?

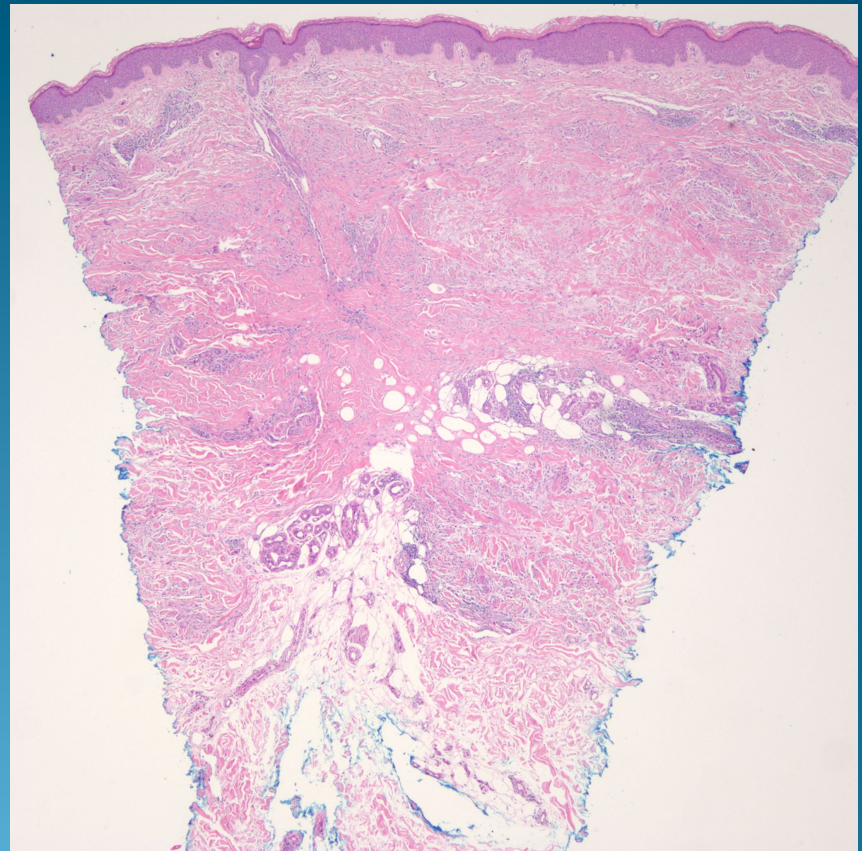
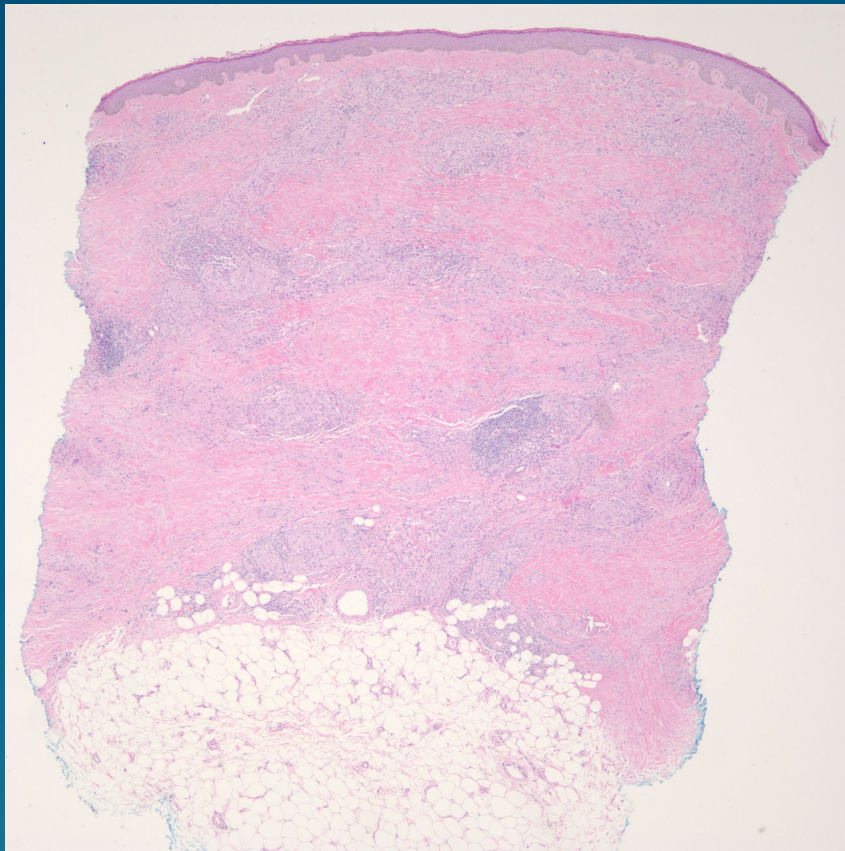




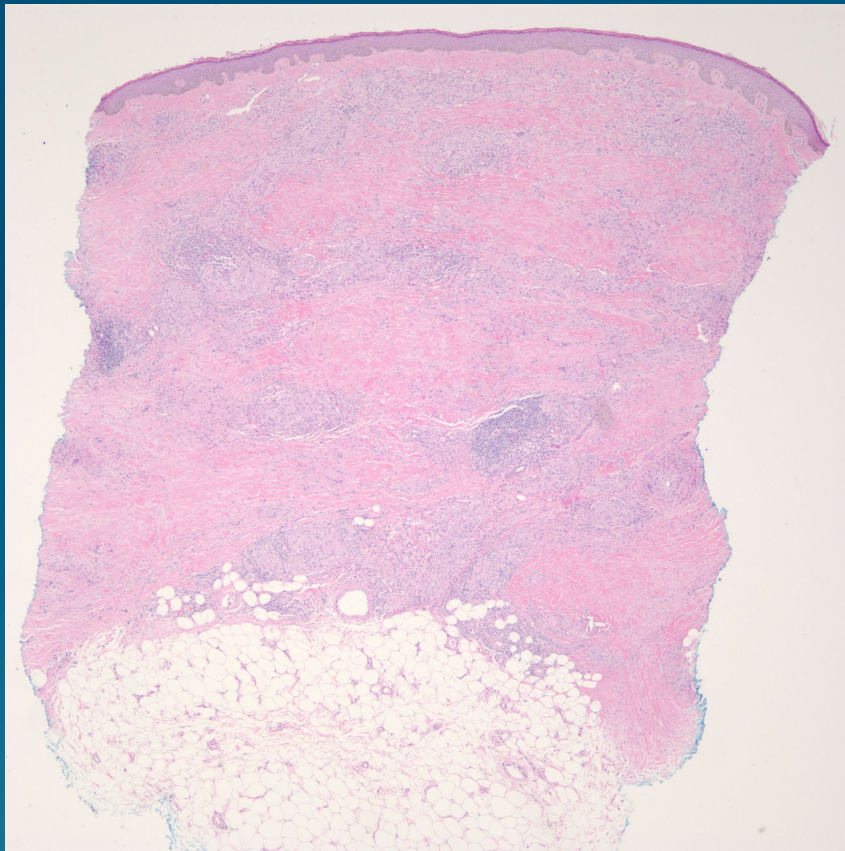




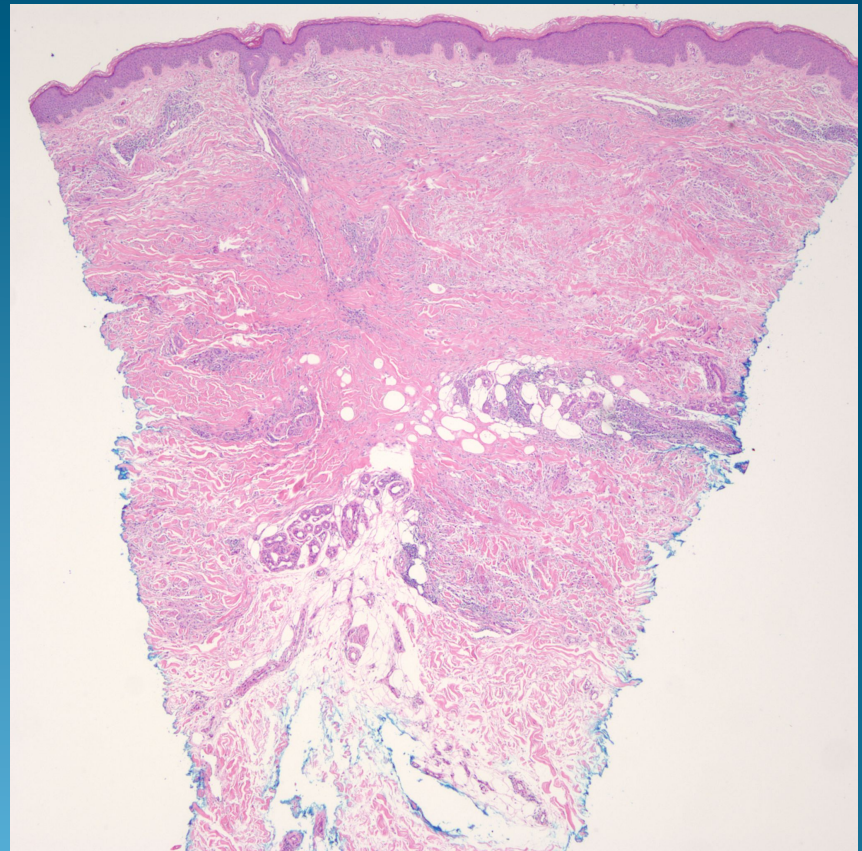
Granuloma Annulare or Necrobiosis Lipoidica?



Necrobiosis Lipoidica



Granuloma Annulare



Necrobiosis Lipoidica

- Staircase layered necrobiosis extending to subcutaneous fat
- Necrobiosis rimmed by chronic inflammatory infiltrate with numerous plasma cells, histiocytes, giant cells, and lymphocytes
- Mucinosis present but not abundant

Granuloma Annulare

- Necrobiosis in expansile nodule, usually superficial dermis but may extend to reticular dermis
- Necrobiosis rimmed by lymphocytes, histiocytes, and giant cells-plasma cells uncommon
- Mucinosis consistently present and may be abundant